

# MIND THE GAP

- A HANDBOOK OF CLINICAL SIGNS IN BLACK AND BROWN SKIN -

MUKWENDE M, TAMONY P, TURNER M

FIRST EDITION



# CONTENTS

Introduction .....	2
GMC- Equality, diversity and inclusion strategy 2018-20.....	2
Authors & Acknowledgements .....	3
<b>BASICS</b> .....	4
Palmar Pallor .....	4
Conjunctival Pallor .....	5
Central Cyanosis .....	6
Erythema .....	8
Swelling (oedema) .....	9
<b>HANDS</b> .....	10
Nail Pitting .....	10
Melanonychia.....	11
Clubbing.....	12
Warts (HPV).....	13
<b>HEAD &amp; NECK</b> .....	14
Tinea Capitis .....	14
Jaundice .....	15
Stomatitis .....	16
Goitre .....	17
<b>REST OF THE BODY</b> .....	18
Meningococcal Disease .....	18
Ichthyosis.....	19
Keloid Scarring .....	20
Bruising .....	21
Dermal Melanocytosis .....	22
Ulcer .....	23
Vesicle/Bulla .....	24
Chickenpox .....	25
Eczema Herpeticum .....	26
Measles.....	27
Molluscum Contagiosum .....	28
<b>REFERENCES</b> .....	29
Want to contribute? .....	31

# INTRODUCTION

There is more and more literature on the need for medical schools to address the equality and diversity agenda in order to ensure that future doctors can effectively treat the diverse population in the UK. The COVID-19 pandemic has highlighted how marginalised and particularly BME communities have poorer health outcomes. If medicine does not decolonize its curriculum and teach students to recognise signs and symptoms on darker skin tones there will be delays in diagnosis or misdiagnosis (Gishen & Lokugamage 2019). As well as offering images of conditions on black and brown skins frequently omitted in text books we have also looked at language and descriptors that often assume the patient is white.

## GMC- EQUALITY, DIVERSITY

*"The principles of equality, diversity and fair treatment are embedded in our core ethical standards and requirements that doctors must meet in medical education and training. Implementing this strategy is a contribution to improving standards of care for all patients by raising awareness of our expectations and making sure:*

- Doctors are equipped to treat the diversity of patients and services users in the UK population, irrespective of where they train*
- Doctors are able to use their diverse backgrounds and experiences to deliver innovative care that can respond to the diverse needs of their patients..."*

# AUTHORS & ACKNOWLEDGEMENTS

## CO-AUTHORS

Malone Mukwende, Medical Student

Dr Peter Tamony, Clinical Lecturer

Margot Turner, Senior Lecturer

## CONTRIBUTORS & ACKNOWLEDGMENTS

Many thanks to all those who helped with the Student-Staff partnership and the development of this handbook. We are particularly thankful to:

- Student Experience Action Group (SEAG)
- Paramedic Faculty (Dave Parr, Chris Baker)
- St George's African-Caribbean Society
- Clinical Skills Team (Dr R Nagaj, Dr H Khan, Dr S Sivakumaran, Dr S Green, Dr J Mogford, Dr P Sivanathan, Dr N Farrell)
- eLearning Unit (Luke Woodham, Sheetal Kavia)
- Dr Tarisai Mandishona

## IMAGES

We are grateful to those who allowed us to use their images for this handbook. All rights reserved by the image owners.

## RECOMMENDED RESOURCES:

British Association of Dermatologists: a handbook for medical students and junior doctors

[https://www.bad.org.uk/library-media/documents/Dermatology%20Handbook%20for%20medical%20students%202nd%20Edition%202014%20Final2\(2\).pdf](https://www.bad.org.uk/library-media/documents/Dermatology%20Handbook%20for%20medical%20students%202nd%20Edition%202014%20Final2(2).pdf)

Oladokun R et al. Atlas of Paediatric HIV Infection

<http://openbooks.uct.ac.za/hivatlas/index.php/hivatlas/catalog/book/3>

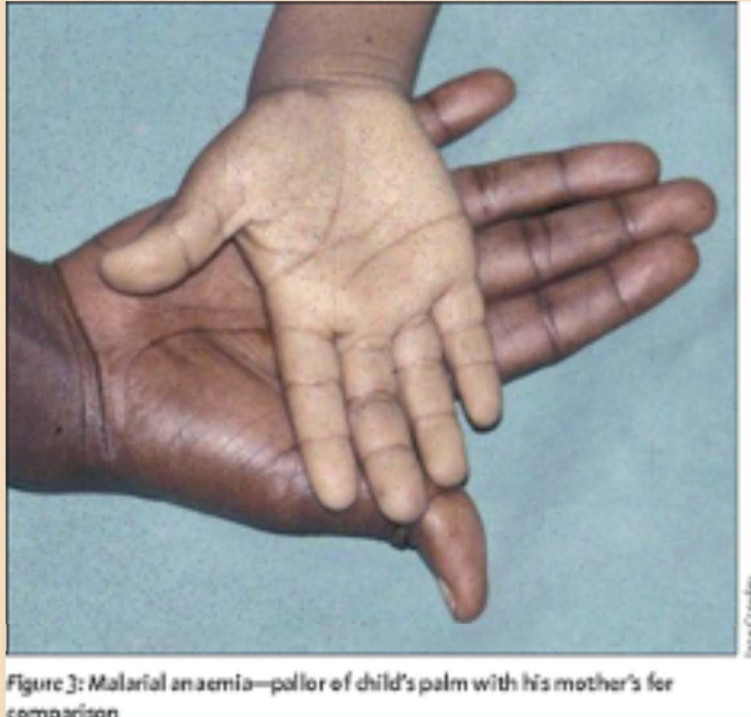DermNet NZ <https://dermnetnz.org/>

Brown Skin Matters <https://www.instagram.com/>

[brownskinmatters](https://www.instagram.com/brownskinmatters)

# BASICS

## PALMAR PALLOR



**SOURCE:** Image from Crawley J et al. Malaria in Children. The Lancet. 2010; 375.

[https://www.semanticscholar.org/paper/Malaria-in-children-Crawley-Chu/](https://www.semanticscholar.org/paper/Malaria-in-children-Crawley-Chu/e6a3b573e38d72c0f85f2e41e4aa0974a17a17db/figure/2)

[e6a3b573e38d72c0f85f2e41e4aa0974a17a17db/figure/2](https://www.semanticscholar.org/paper/Malaria-in-children-Crawley-Chu/e6a3b573e38d72c0f85f2e41e4aa0974a17a17db/figure/2) (accessed 11/03/20)

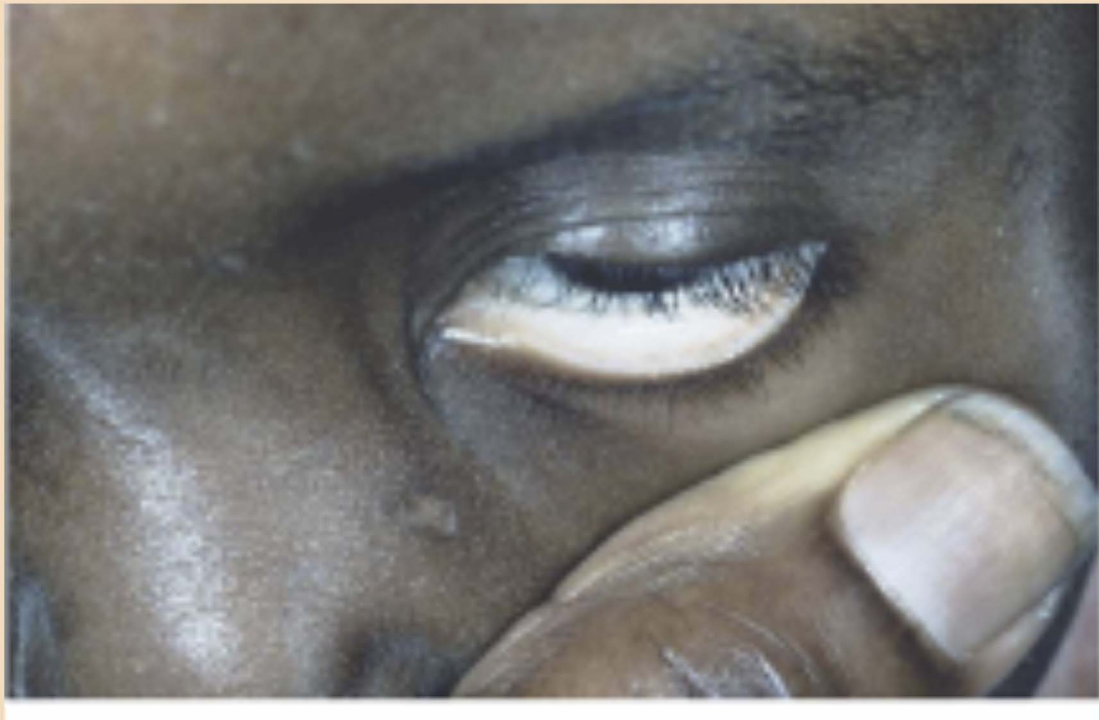
**WHAT IT IS:** Pallor refers to the pale appearance of skin due to reduced oxyhaemoglobin levels.

This may occur in anaemia or shock.

**HOW IT IS IDENTIFIED:** Pallor may be identified by asking the patient to turn their palms to face the ceiling (supination). In particular there is reduced darkness in the palmar creases. It is useful to compare the patient's palms with your own or that of an accompanying family member (e.g. parent or sibling). Sensitivity and specificity is not particularly high so clinical correlation is advised.

# BASICS

## CONJUNCTIVAL PALLOR



**SOURCE:** Image from Breman J, Holloway C. Malaria surveillance counts. The American Journal of Tropical Medicine and Hygiene. 2007.

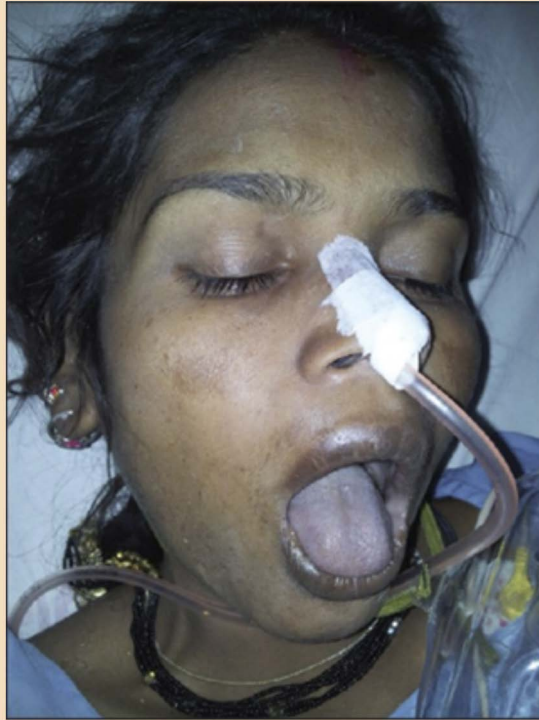<https://www.semanticscholar.org/paper/Malaria-surveillance-counts.-Breman-Holloway/807bdf8d5a5193d7f3a1c6ffde41f570355a1dd1/figure/5> (accessed 11/03/20)

**WHAT IT IS:** As with the palms, pallor refers to the pale appearance of skin due to reduced oxyhaemoglobin levels. This may occur in anaemia or shock.

**HOW IT IS IDENTIFIED:** Pallor may be identified by pulling down (or asking the patient to pull down) the lower eyelid. The palpebral conjunctiva is usually a healthy pink due to the blood supply of the vascular bed. In anaemia it will appear a pale pink or white (regardless of skin colour)

# BASICS

## CENTRAL CYANOSIS



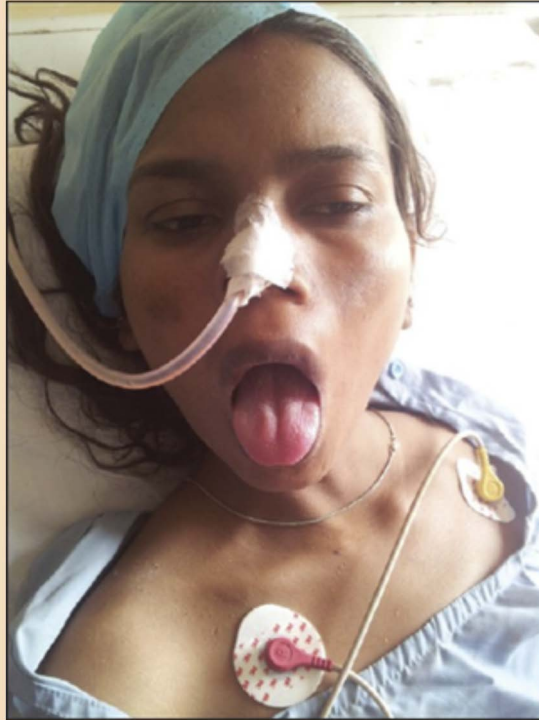**SOURCE:** Image (used under CC licence CC BY-SA 4.0) from Singhai A et al. Methemoglobinaemia. Journal of Dr. NTR University of Health Sciences. 2013. [http://www.idrntruhs.org/viewimage.asp?img=JNTRUnivHealthSci\\_2013\\_2\\_2\\_154\\_112359\\_f1.jpg](http://www.idrntruhs.org/viewimage.asp?img=JNTRUnivHealthSci_2013_2_2_154_112359_f1.jpg) (accessed 11/03/20) <https://creativecommons.org/licenses/by-sa/4.0/>

**WHAT IT IS:** Cyanosis refers to a blue or grey discolouration of the skin and mucous membranes due to high levels of deoxygenated haemoglobin. This is caused by hypoxaemia (low arterial oxygen). Note that this is distinct from hypoxia which refers to inadequate oxygenation of tissues.

**HOW IT IS IDENTIFIED:** The ability to detect cyanosis on visual inspection depends on “dermal thickness, cutaneous pigmentation, and the state of the cutaneous capillaries”. It is therefore best to look for cyanosis where the epidermis is thin and the vascular supply is abundant such as the lips or more importantly the oral mucous membranes (buccal, sublingual). This is known as central cyanosis. Cyanosis detected in the hands and feet is known as peripheral cyanosis. Peripheral cyanosis may occur with or without central cyanosis, and is more difficult to detect in dark skin.

# BASICS

## CENTRAL CYANOSIS



**SOURCE:** Image (used under CC licence CC BY-SA 4.0) from Singhai A et al. Methemoglobinaemia. Journal of Dr. NTR University of Health Sciences. 2013. [http://www.idrntruhs.org/viewimage.asp?img=JNTRUnivHealthSci\\_2013\\_2\\_2\\_154\\_112359\\_f2.jpg](http://www.idrntruhs.org/viewimage.asp?img=JNTRUnivHealthSci_2013_2_2_154_112359_f2.jpg) (accessed 11/03/20) <https://creativecommons.org/licenses/by-sa/4.0/>

**WHAT IT IS:** Normoxaemia refers to having a normal concentration of arterial oxygen

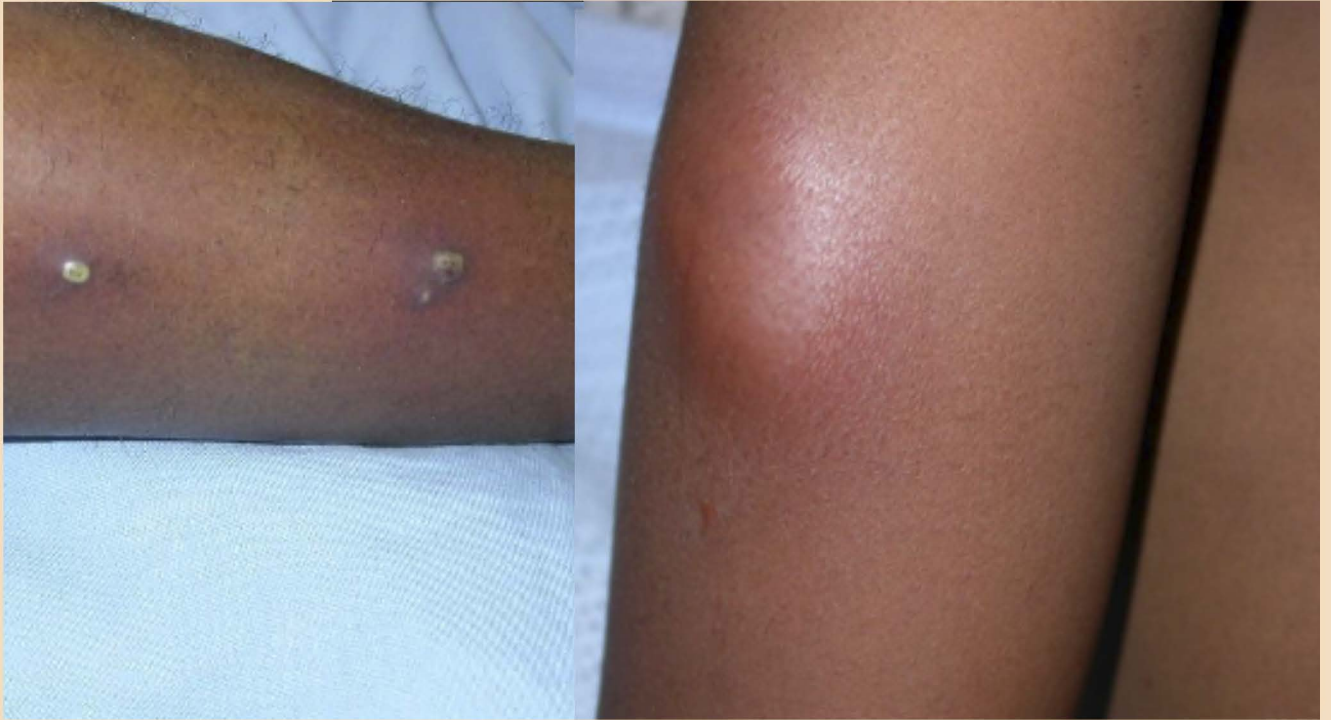**HOW IT IS IDENTIFIED:** Please note the difference between the same patient pre- and post-oxygen therapy. Post-oxygen therapy the patient's tongue and lips have a healthy pink colour due to correction of arterial oxygen and subsequent tissue oxygenation. The facial skin now appears it's usual colour, not the “ashen” (pale grey/blue) tone associated with cyanosis.

**DESCRIPTIONS ADAPTED FROM:** McMullen S, Patrick W. The American Journal of Medicine. Cyanosis. 2013. <https://doi.org/10.1016/j.amjmed.2012.11.004> (accessed 11/03/20)



# BASICS

## ERYTHEMA



**SOURCE:** Image (used under CC licence CC BY-SA 4.0) from Atlas of Paediatric HIV Infection.

Oladokun R et al

<https://openbooks.uct.ac.za/uct/catalog/view/hivatlas/23/655-2>

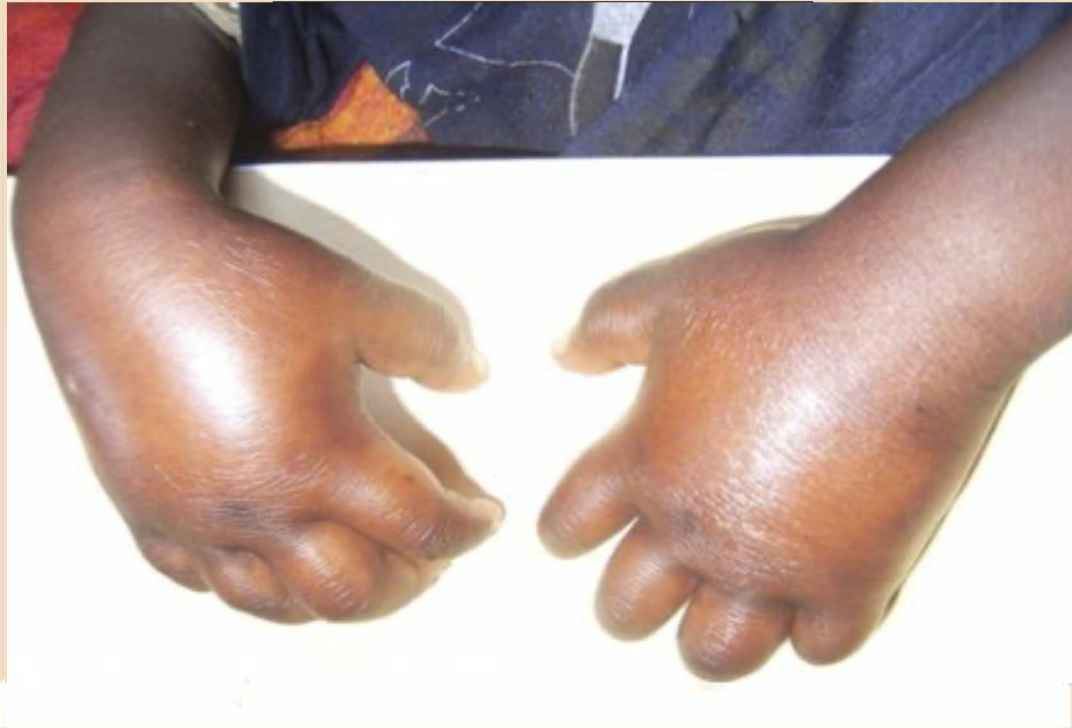<https://creativecommons.org/licenses/by-sa/4.0/>

**WHAT IT IS:** Erythema refers to the red appearance of skin associated with inflammation and infection.

**HOW IT IS IDENTIFIED:** In the first image (folliculitis) you will note the red/purple hue immediately surrounding the pustules. The patient's regular skin tone is best appreciated in the area directly in between the two pustules (mid-shin). Detection of erythema in the second picture is aided by the swelling which pulls the skin tight and gives it a smooth and shiny appearance with a burgundy undertone.

# BASICS

## SWELLING ( O E D E M A )



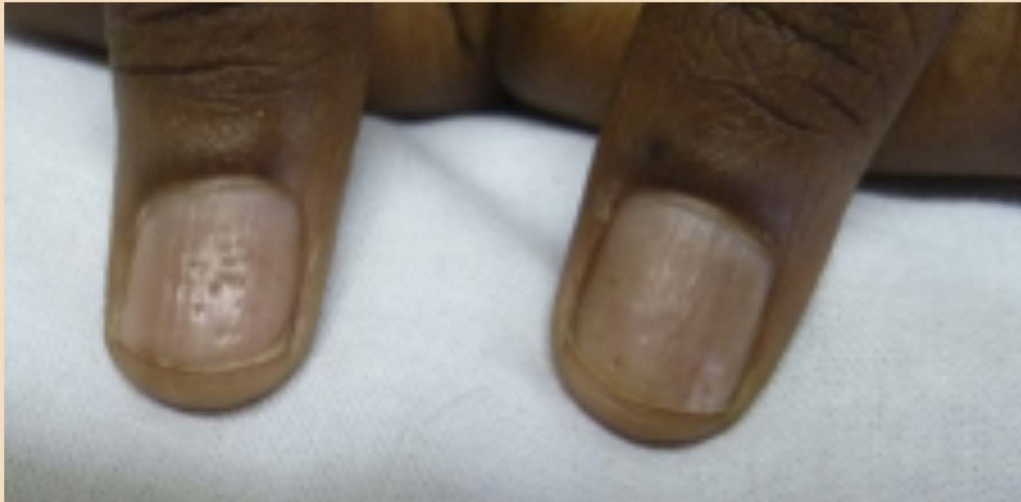**SOURCE:** Image (used with permission- Copyright Clearance Centre Licence Number: 4785430529159) from Matthews C et al. Sick cell disease in childhood. BMJ. 2014; 348 <https://www.bmj.com/content/348/sbmj.g115> (accessed 11/03/20)

**WHAT IT IS:** Oedema refers to swelling due to excess fluid. This occurs in a number of conditions including heart failure, allergy and trauma.

**HOW IT IS IDENTIFIED:** Swelling can be observed where body tissues appear larger than normal. Heart failure may result in swollen ankles & legs. You may see pitting where an indentation remains after pressing the affected area (some patients will have marked indentations along their sock line). Oedema of the neck and airways will result in breathing difficulties and characteristic gurgling/stridor. Joint swelling in this image is a result of dactylitis (inflammation of the digits) caused by a sickle cell crisis. Note that the hands and fingers appear “puffy” and the skin is taut and shiny. It is vital that any rings or jewellery are removed before swelling becomes severe.

# HANDS

## NAIL PITTING



**SOURCE:** Image © Copyright Newcastle University and Northumbria University 2020. All rights reserved. From Paediatric Musculoskeletal Matters.

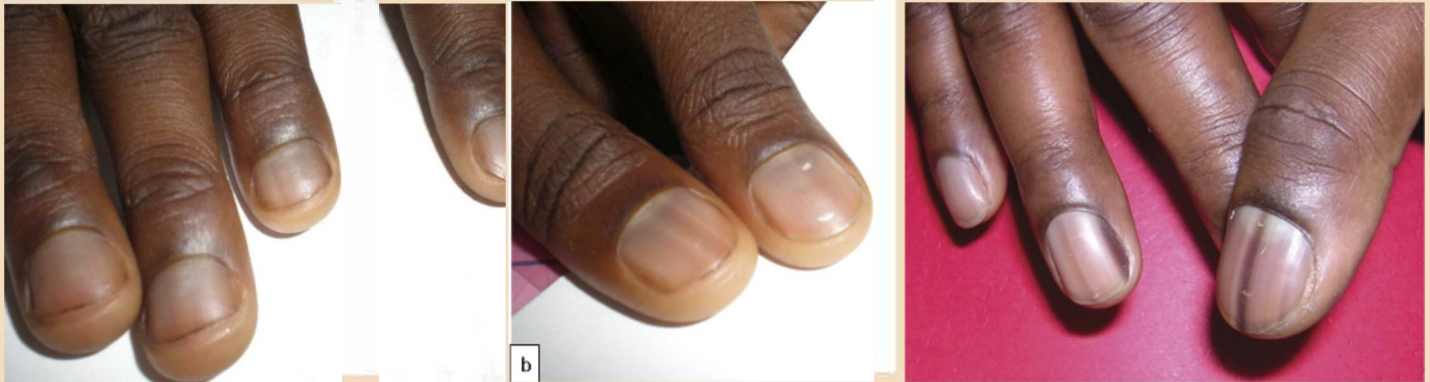<http://www.pmmonline.org/page.aspx?id=1643> (accessed 27 February 2020) used with permission

**WHAT IT IS:** Nail pitting refers to pin-size depressions on the surface of nails.

**HOW IT IS IDENTIFIED:** The indentations in the above picture are often associated with psoriasis which typically causes silvery skin plaques on the extensor surfaces of joints. The nail pitting itself is often irregular in pattern and may affect one, some or all of the fingernails or even toenails.

# HANDS

## MELANONYCHIA



**SOURCE:** Left & central images (used under CC licence CC BY-SA 4.0) from Atlas of Paediatric HIV Infection. Oladokun R et al

<https://openbooks.uct.ac.za/uct/catalog/view/hivatlas/23/652-2> (accessed 22/05/20)

<https://creativecommons.org/licenses/by-sa/4.0/>

Right image © Copyright Thomas Jefferson University. All rights reserved. From Tully A et al. Evaluation of Nail Abnormalities. American Family Physician. 2012; 85(8)

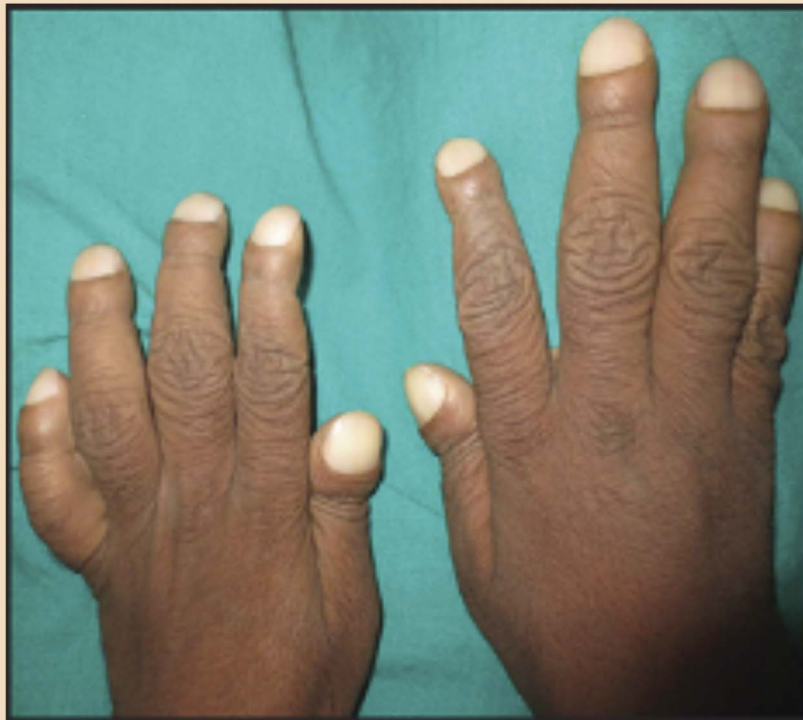<https://www.aafp.org/afp/2012/0415/p779.html> (accessed 11/03/20)

**WHAT IT IS:** Longitudinal melanonychia refers to a pigmented line that runs vertically along the nail. It is caused by deposition of melanin from melanocytes in the proximal nail matrix.

**HOW IT IS IDENTIFIED:** These black or brown lines may occur in some or all of the fingernails. The lines may be diffuse and light in shade or be darker and form a longitudinal band. They can vary in width and position. The lines in the images are mainly centrally positioned but they may also occur more laterally. Melanonychia is a normal variant in up to 90% of black people. It may however, represent a subungual melanoma (melanoma of the nailbed). Melanomas typically have a wide (>3mm), new and changing band in a single nail.

# HANDS

## CLUBBING



**SOURCE:** Image (used under CC licence CC BY-SA 4.0) from Desai V et al. Familial primary osteoarthropathy: A case report with unusual dental findings. Journal of Indian Academy of Oral Medicine and Radiology. 2015 (27)4: p620-624 (used under CC license)

[http://www.jiaomr.in/viewimage.asp?img=JIndianAcadOralMedRadiol\\_2015\\_27\\_4\\_620\\_188777\\_f2.jpg](http://www.jiaomr.in/viewimage.asp?img=JIndianAcadOralMedRadiol_2015_27_4_620_188777_f2.jpg)

(accessed 20/03/20)

<https://creativecommons.org/licenses/by-sa/4.0/>

**WHAT IT IS:** Clubbing refers to the “bulbous swelling of the soft tissue of the terminal phalanx of a digit”. Clubbing is associated with a large number of conditions affecting a number of different body systems. These include lung cancer, bronchiectasis, cystic fibrosis, inflammatory bowel disease, coeliac disease, endocarditis, Graves’ disease, and liver disease to name a few. The exact mechanism is unknown.

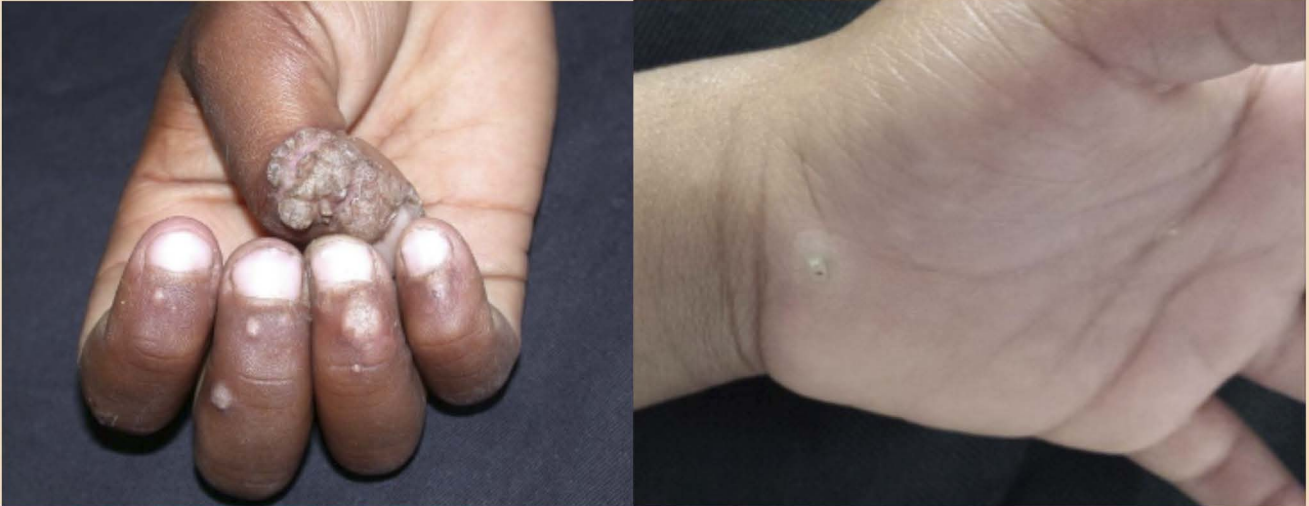**HOW IT IS IDENTIFIED:** Clubbing presents as periungual erythema and softening of the nailbed followed by an increase in Lovibond’s angle (angle between the nailbed and nailplate). As this develops the nail become more curved (increased convexity). You can test for loss of the nail angle by looking for Schamroth’s window. When palpating the digit the nailbed will feel soft and the nail ballotable. In severe clubbing (such as the image above) the distal part of the digit becomes swollen and bulbous.

**DESCRIPTION ADAPTED FROM:** BMJ Best Practice: Assessment of Clubbing

<https://bestpractice.bmj.com/topics/en-gb/623> (accessed 22/05/20)

# HANDS

## WARTS (HPV)



**SOURCE:** Images (used under CC licence CC BY-SA 4.0) from Atlas of Paediatric HIV Infection.

Oladokun R et al

<https://openbooks.uct.ac.za/uct/catalog/view/hivatlas/23/656-2> (accessed 22/05/20)

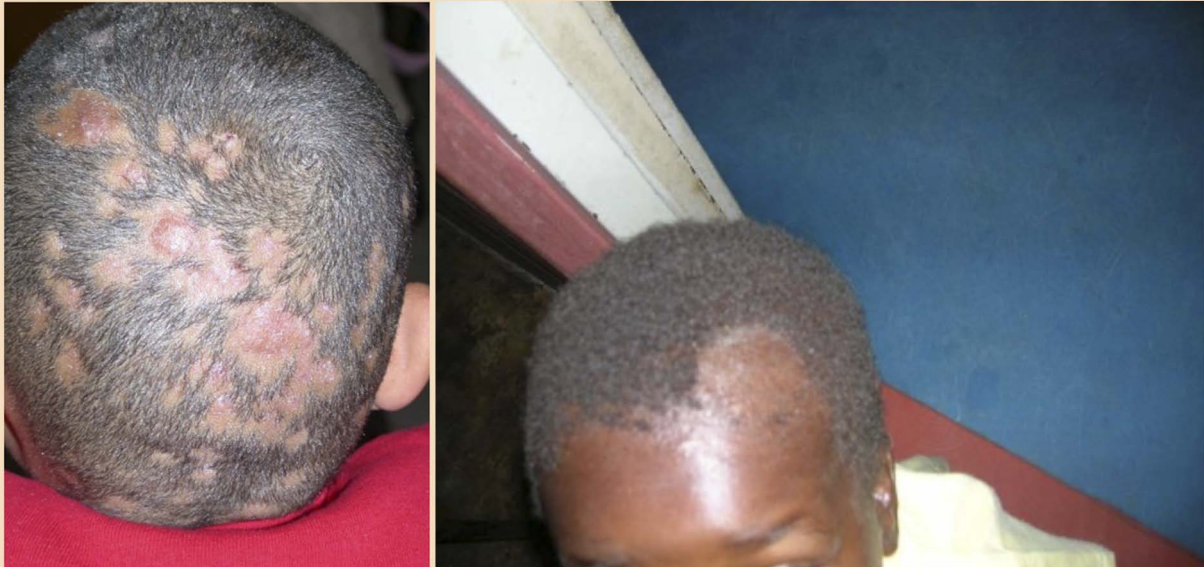<https://creativecommons.org/licenses/by-sa/4.0/>

**WHAT IT IS:** Warts are benign soft tissue swellings which are caused by the human papilloma virus (HPV).

**HOW IT IS IDENTIFIED:** There are a number of different subtypes. Common warts typically affect the digits and web spaces of the hands presenting as firm, well circumscribed papules. Plantar warts (verrucae) occur on the palmar surface of the hands and the plantar surface (sole) of the feet. There are also filiform, periungual, flat and cauliflower types. For black and brown skin types warts may appear paler than surrounding skin

# HEAD AND NECK

## TINEA CAPITIS



**SOURCE:** Images (used under CC licence CC BY-SA 4.0) from Atlas of Paediatric HIV Infection. Oladokun R et al

<https://openbooks.uct.ac.za/uct/catalog/view/hivatlas/23/657-2> (accessed 22/05/20)

<https://creativecommons.org/licenses/by-sa/4.0/>

**WHAT IT IS:** A ringworm (fungal) infection affecting the scalp. The dermatophyte fungi (most commonly *Trichophyton tonsurans*) live on the epidermis and hair. It can lead to scarring of the skin and secondary bacterial infections.

**HOW IT IS IDENTIFIED:** Tinea capitis may cause patchy alopecia as infection of the hairs causes them to become brittle and break easily. Infection of the skin causes erythema (note the slightly red hue on the left image) and itching. The skin will appear dry and flaky. It is most common in children aged 3 to 9 and is more prevalent in patients from African-Caribbean backgrounds.

**DESCRIPTION ADAPTED FROM:** Ely J, Rosenfield S. Diagnosis and Management of Tinea Infections. *American Family Physician*. 2014; 90(10): p702-711

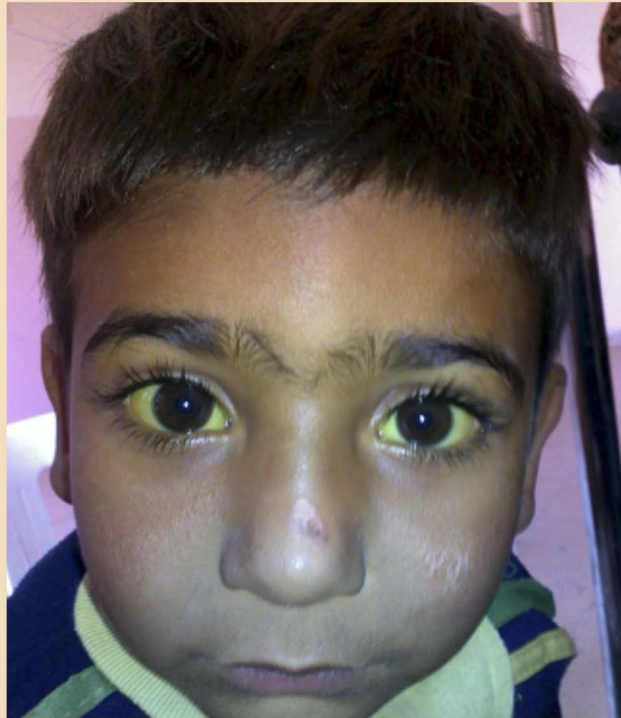<https://www.aafp.org/afp/2014/1115/p702.html> (accessed 22/05/20) and

British Association of Dermatologists. Tinea Capitis Patient Information Leaflet. 2014

<https://www.bad.org.uk/for-the-public/patient-information-leaflets/tinea-capitis> (accessed 22/05/20)

# HEAD AND NECK

## J A U N D I C E



**SOURCE:** Image from Wikimedia Commons [User: Sab3el3eish] (used with CC licence CC BY 3.0)

<https://commons.wikimedia.org/wiki/File:Jaundice.jpg> (accessed 20/03/20)

<https://creativecommons.org/licenses/by/3.0/>

**WHAT IT IS:** Jaundice refers to yellow discolouration of the skin and soft tissues due to hyperbilirubinaemia causing bile pigment deposition. Jaundice may be a result of various pre-, intra-, and post-hepatic causes.

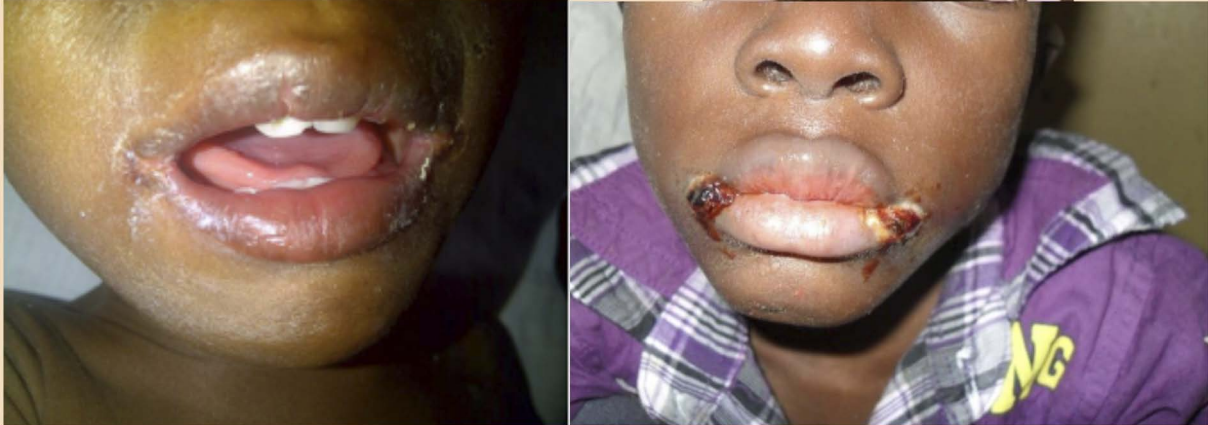**HOW IT IS IDENTIFIED:** In dark skin, jaundice might only produce subtle yellow discolouration. The patient themselves or their family members might have noticed a change. It is useful to compare the patient's skin to their family members (if possible) or previous pictures of themselves. Eye signs are more obvious; icterus of the conjunctival membrane which overlies the sclera will make the 'white of the eyes' appear yellow.



---

# HEAD AND NECK

## STOMATITIS



**SOURCE:** Images (used under CC licence CC BY-SA 4.0) from Atlas of Paediatric HIV Infection. Oladokun R et al

Left Image: <https://openbooks.uct.ac.za/uct/catalog/view/hivatlas/23/660-1>

Right image: <https://openbooks.uct.ac.za/uct/catalog/view/hivatlas/23/656-2> (accessed 22/05/20)

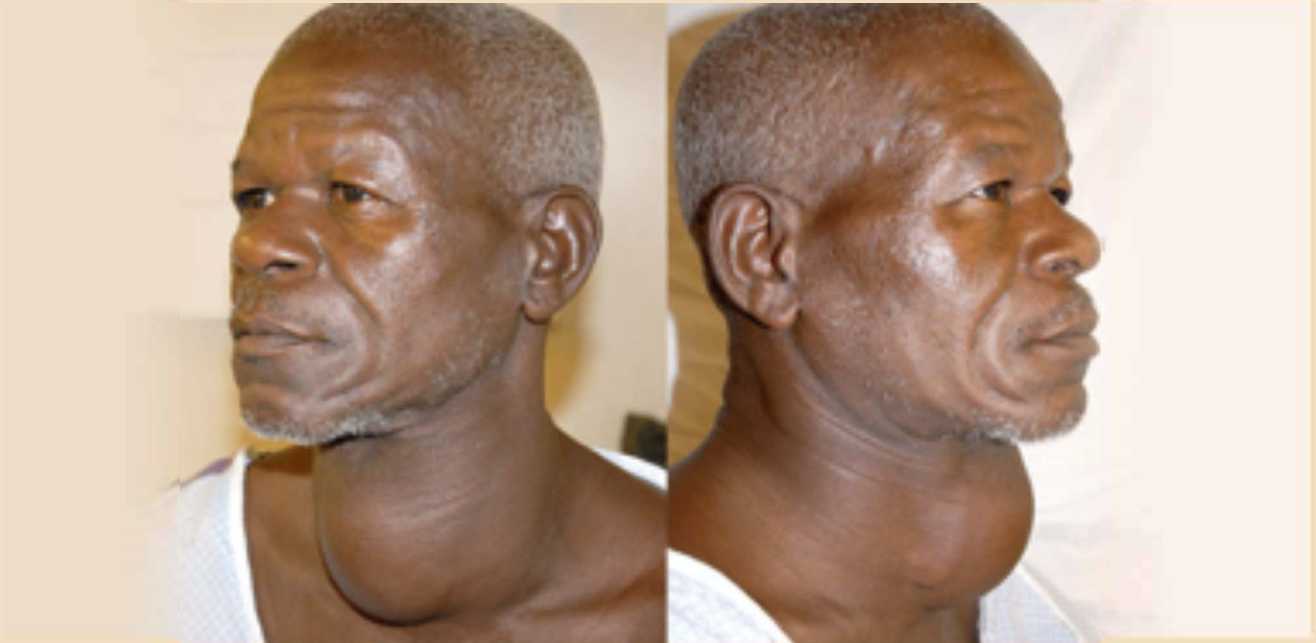<https://creativecommons.org/licenses/by-sa/4.0/>

**WHAT IT IS:** Inflammation the mucous membranes of the mouth

**HOW IT IS IDENTIFIED:** Stomatitis commonly presents as cracking of the corners of the lips (angular cheilitis). This is painful and may be associated with erythema, ulceration & oedema. It may be associated with B vitamin deficiency, iron deficiency and contact dermatitis (irritant and allergic).

# HEAD AND NECK

## GOITRE



**SOURCE:** Images © Copyright 2017 Beta Charitable Trust. All rights reserved.

From <http://www.betacharitabletrust.org/projects/goitre-operations> (accessed 18/05/20)”

**WHAT IT IS:** A goitre refers to neck swelling due to an enlarged thyroid gland. Most goitres are benign but they can also be a sign of cancer. Causes of goitre include Graves disease, Hashimoto's, thyroiditis, iodine deficiency.

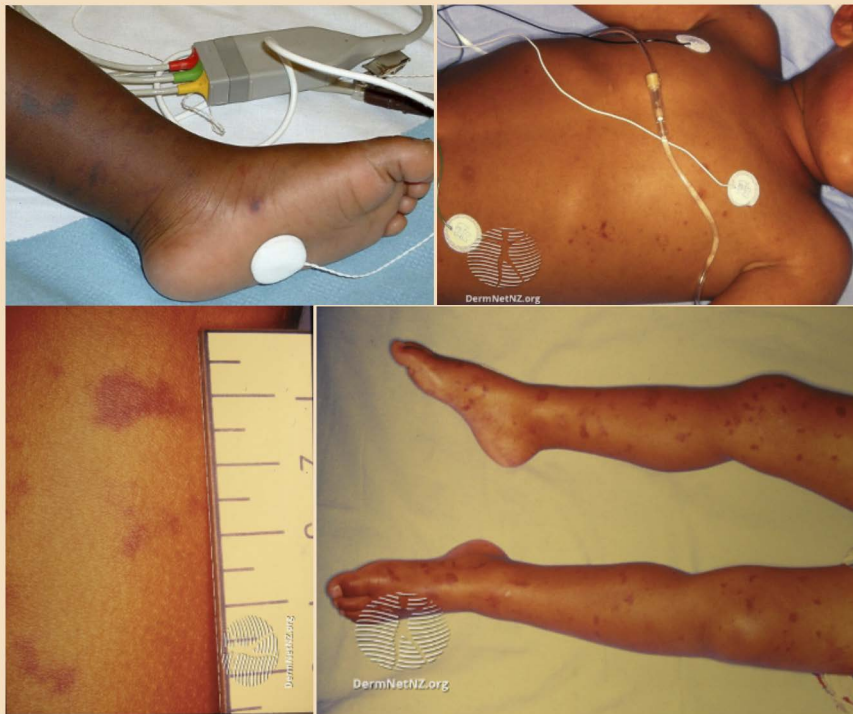**HOW IT IS IDENTIFIED:** Swelling to the anterior-inferior aspect of the neck. They may be further classified into: diffuse smooth goitre (entire gland enlarged), multinodular goitre (numerous nodules/lumps), single nodule (solitary lump).

**DESCRIPTION AMENDED FROM:** Starr O. Goitre. 2020

<https://patient.info/hormones/overactive-thyroid-gland-hyperthyroidism/goitre-thyroid-swelling>  
(accessed 18/05/20)

# REST OF THE BODY

## M E N I N G O C O C C A L   D I S E A S E



**SOURCE:** Images from (used under CC licence CC BY-NC-ND 3.0 NZ)

<https://dermnetnz.org/topics/meningococcal-disease/> (accessed 20/03/20)

<https://creativecommons.org/licenses/by-nc-nd/3.0/nz/>

Top left Image © Copyright Meningitis Research Foundation. All rights reserved. From <https://www.meningitis.org/meningitis/check-symptoms/babies> (accessed 18/05/20)

**WHAT IT IS:** Meningococcal disease refers to meningitis and meningococcal septicaemia caused by the *Neisseria meningitidis* bacteria.

**HOW IT IS IDENTIFIED:** Look for the “pin-prick” rash in any unwell child. The child may also have a fever, breathing difficulties, difficulty rousing and high-pitched cry amongst other symptoms. The petechiae (small red/purple/brown purpura) do not disappear when pressure is applied to the skin in 50-75% of cases (non-blanching). They are caused by bleeding into the skin. Maculopapular rashes can also appear. These patches can become larger and lead to tissue necrosis. Any part of the body may be affected but it most commonly affects the trunk and limbs. Particular attention should be paid to dark skin as lesions might be subtle. Ensure adequate lighting and ask the patient’s parents if they have noticed any new marks. Lesions should be documented accurately. Do not delay treatment, meningococcal disease is a medical emergency.

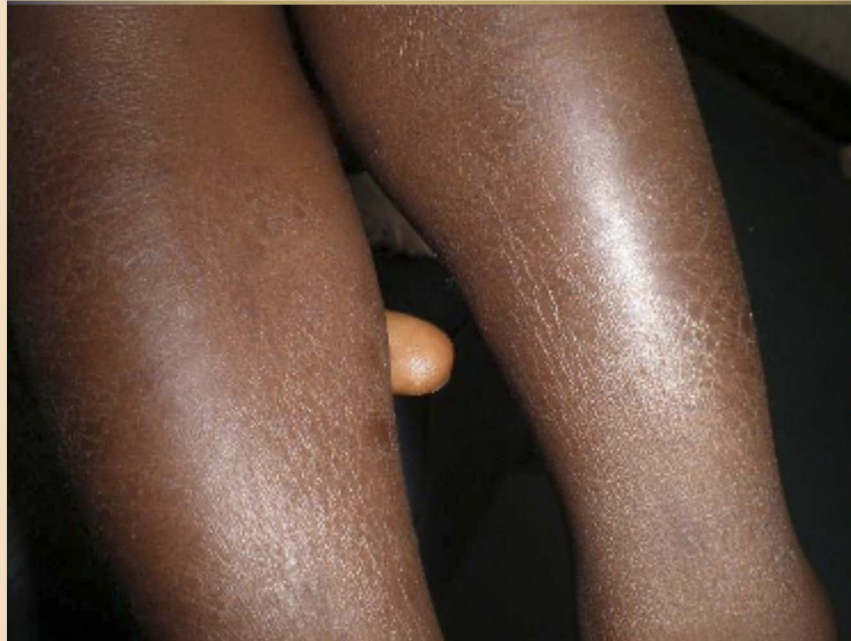
**DESCRIPTION AMENDED FROM:** DermNet NZ

<https://dermnetnz.org/topics/meningococcal-disease/> (accessed 18/05/20)

[www.blackandbrownskin.co.uk](http://www.blackandbrownskin.co.uk)

# REST OF THE BODY

## ICHTHYOSIS



**SOURCE:** Image (used under CC licence CC BY-SA 4.0) from Atlas of Paediatric HIV Infection.

Oladokun R et al

<https://openbooks.uct.ac.za/uct/catalog/view/hivatlas/23/654-2>

<https://creativecommons.org/licenses/by-sa/4.0/>

**WHAT IT IS:** Ichthyosis is the “continual and widespread scaling of the skin”. It is commonly inherited but may also be acquired as a result of other conditions (e.g. renal disease). The characteristic appearance is caused by accumulation of dead skin cells.

**HOW IT IS IDENTIFIED:** Skin may have a “fish-scale” appearance. Skin is dry and rough to touch. It most commonly affects the limbs and spares skin folds. Skin may appear darker and thicker over affected areas such as the shins. The “cracks” between scales will appear lighter in colour.

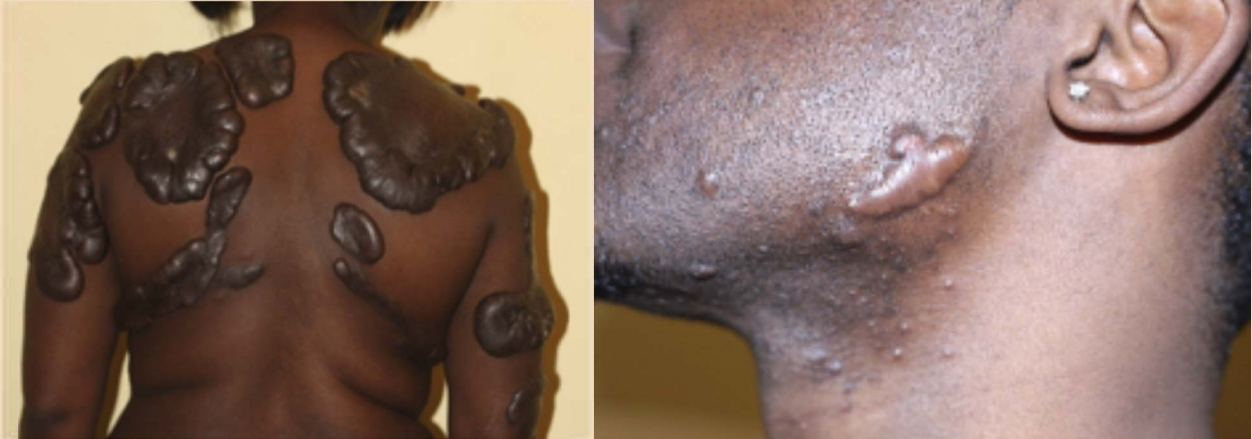**DESCRIPTION AMENDED FROM:** Mayo Clinic. Ichthyosis Vulgaris.

<https://www.mayoclinic.org/diseases-conditions/ichthyosis-vulgaris/symptoms-causes/syc-20373754>

(accessed 18/05/20)

# REST OF THE BODY

## KELOID SCARRING



**SOURCE:** Images from Wikimedia Commons [User: Htirgan] (CC licence CC BY-SA 3.0)

[https://commons.wikimedia.org/wiki/File:Massive\\_Keloids.jpg](https://commons.wikimedia.org/wiki/File:Massive_Keloids.jpg) (accessed 18/05/20)

[https://commons.wikimedia.org/wiki/File:Keloid-Face\\_Semi\\_Flat,\\_Facial\\_Keloid.JPG](https://commons.wikimedia.org/wiki/File:Keloid-Face_Semi_Flat,_Facial_Keloid.JPG) (accessed 18/05/20)

<https://creativecommons.org/licenses/by-sa/3.0/>

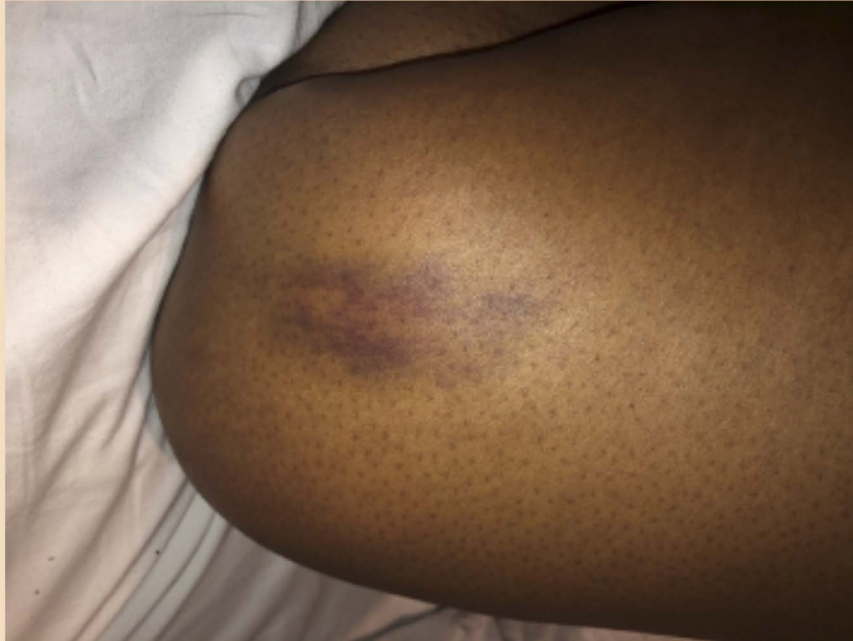**WHAT IT IS:** Keloid scarring refers to thick, enlarged scars which are bigger than the original wound. They can form following minor skin damage or even spontaneously. There is an overproduction of collagen but the exact mechanism for keloid scar formation is not understood. They are more common in people with dark skin.

**HOW IT IS IDENTIFIED:** Keloid scars are often raised and firm to touch. They may be skin coloured or darker than surrounding skin. They are hairless. They commonly occur on earlobes (following piercing), cheeks (shaving, acne), and upper chest. Massive keloids can be seen in the first image.

---

# REST OF THE BODY

## BRUISING



**SOURCE:** Image from Garikai S, 2020

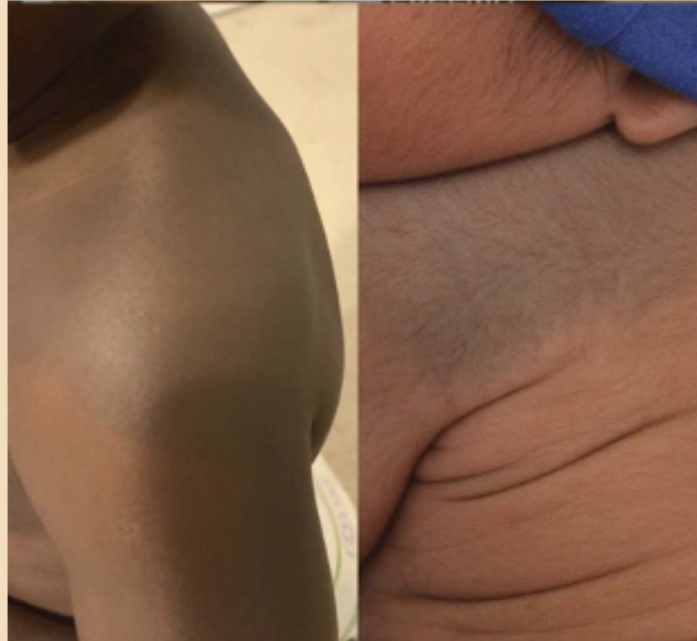**WHAT IT IS:** Ecchymoses (bruising) secondary to trauma. Ecchymosis form when blood vessels near the surface of the skin are damaged. This results in bleeding underneath the skin which remains intact.

**HOW IT IS IDENTIFIED:** Ecchymosis in dark skin may present as a purple or dark brown discoloration. History is important as the size and shape of the bruise(s) will be dependent on the mechanism of injury. The colour of the bruising is likely to change over time but it is not possible to reliably date bruising based on appearance alone. You should always consider coagulopathies and non-accidental injuries. Due to the increased melanin pigmentation, it might be difficult to see immediate bruising (which often appears red in light skin). It might only become obvious as the colour of the bruises develops into a dark purple, brown or black which is darker than the surrounding skin. Similarly, the yellow discoloration of older bruises may be more subtle in darker skin types. Close inspection with comparison of both sides is recommended.

---

# REST OF THE BODY

## DERMAL MELANOCYTOSIS



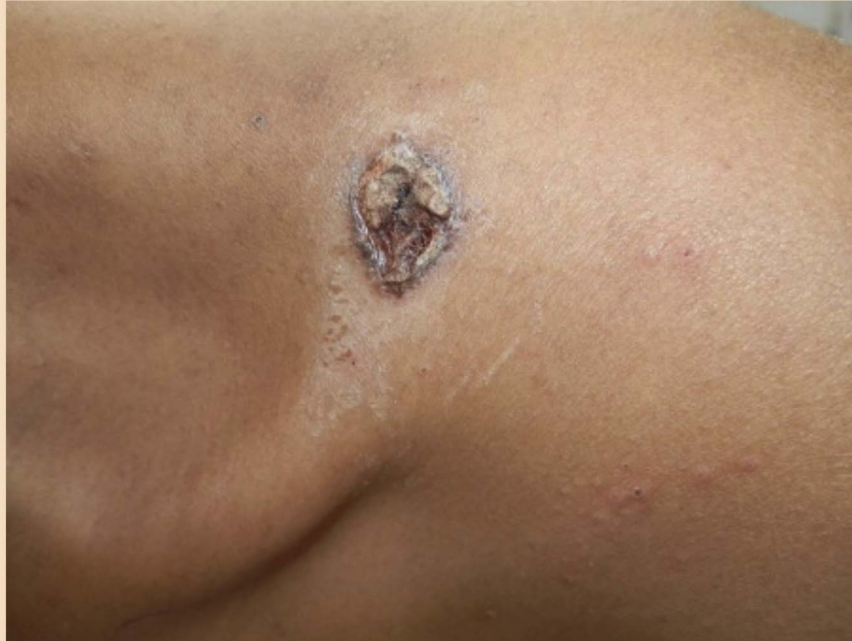**SOURCE:** Images from Brown Skin Matters <https://www.instagram.com/brownskinmatters/>  
(accessed 20/05/20)

**WHAT IT IS:** Dermal melanocytosis, also known as slate-grey naevi, blue-grey spots or Mongolian blue spots, occur due to the entrapment of melanocytes in the dermis of the developing embryo.

**HOW IT IS IDENTIFIED:** Dermal melanocytosis appear as patches that are darker than the surrounding skin. They are found in new-born babies. The spots tend to disappear by the time a child has reached the age of 4. They may look similar in appearance to bruises however dermal melanocytosis tends to be more homogenous and uniform in colour. History and thorough inspection are necessary to avoid misdiagnosing as non-accidental bruising (and vice versa).

# REST OF THE BODY

## U L C E R



**SOURCE:** Images (used under CC licence CC BY-SA 4.0) from Atlas of Paediatric HIV Infection.

Oladokun R et al

<https://openbooks.uct.ac.za/uct/catalog/view/hivatlas/23/655-2> (accessed 20/05/20)

<https://creativecommons.org/licenses/by-sa/4.0/>

**WHAT IT IS:** “A break in an epithelial surface”. There are a large number of causes for skin ulcers including venous, arterial, neuropathic/diabetic, pressure, vasculitis, malignancy (e.g. squamous cell carcinoma) and infectious (e.g. Buruli ulcer or cutaneous leishmaniasis).

**HOW IT IS IDENTIFIED:** Ulcers present as a break or sore in the skin. It is important to establish any history of diabetes, trauma, travel or preceding insect bite. Patients may report a wound that isn't healing. Presence of pain and claudication are vital clues. Examination should detail the site, size, and colour. Presence of pus and/or surrounding erythema may indicate an infected ulcer. Venous ulcers are typically shallow and have an irregular border. Look for a sloughy base (granulating tissue) and signs of venous insufficiency in the legs (venous eczema, haemosiderin deposits, lipodermatosclerosis). Arterial ulcers are typically round and “punched out” (deep with a well-defined border), look for a necrotic base. People with diabetes are at higher risk of developing foot ulcers, ensure you remove their socks and check pressure areas (do not forget to inspect the toes).

**DEFINITION:** Martin E (ed). Concise Medical Dictionary. OUP: Oxford; 9th edition (2015)

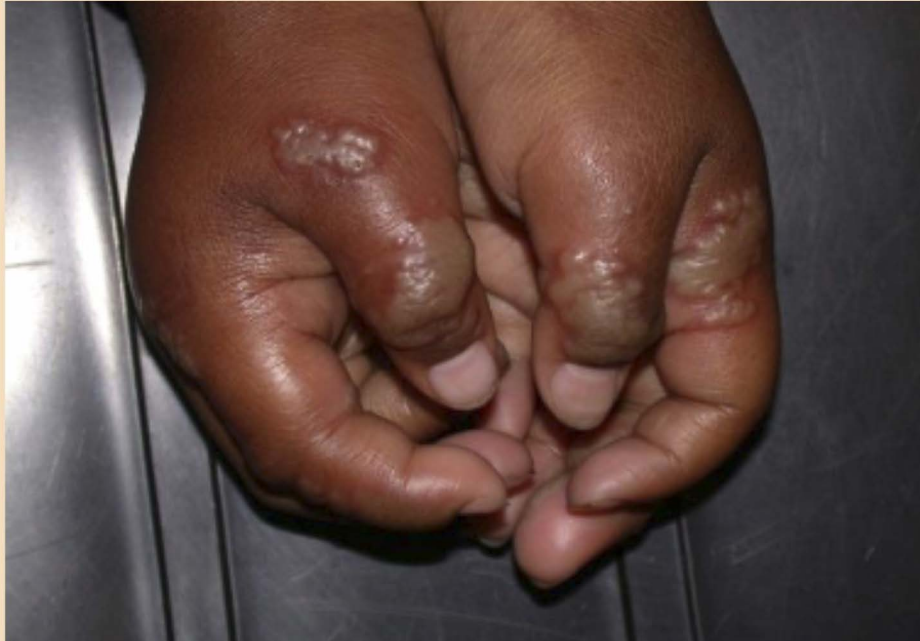**SUGGESTED READING:** <https://patient.info/doctor/leg-ulcers-pro>

[www.blackandbrownskin.co.uk](http://www.blackandbrownskin.co.uk)



# REST OF THE BODY

## VESICLE / BULLA



**SOURCE:** Images (used under CC licence CC BY-SA 4.0) from Atlas of Paediatric HIV Infection. Oladokun R et al

<https://openbooks.uct.ac.za/uct/catalog/view/hivatlas/23/655-2> (accessed 20/05/20)

<https://creativecommons.org/licenses/by-sa/4.0/>

**WHAT IT IS:** A vesicle is a small fluid-filled blister (<5mm diameter), a bulla is a larger fluid-filled blister (>5mm diameter). A pustule is a pus containing lesion (<5mm diameter). There are a wide variety of blistering conditions including herpes simplex, varicella zoster, eczema herpeticum, atopic dermatitis, erythema multiforme, Stevens-Johnson syndrome, staph-scaled skin syndrome, fixed drug eruptions and burns to name but a few.

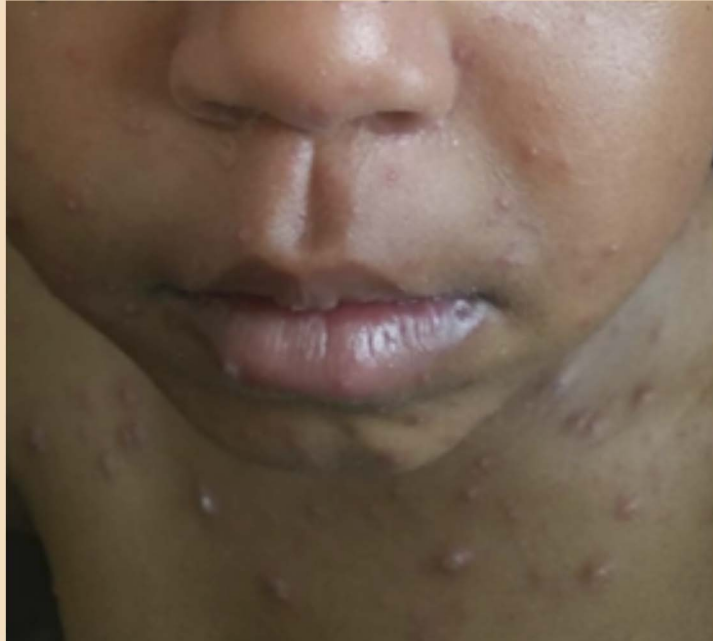**HOW IT IS IDENTIFIED:** Blisters will appear as raised lesions on the skin. They appear lighter in colour than the surrounding skin. Pain is common. The distribution will vary depending on the underlying pathology. The image above shows multiple grouped vesicles (that is they are merged/coalescing), also note the erythematous margins.

**SUGGESTED READING:** <https://dermnetz.org/topics/blistering-skin-conditions/>

---

# REST OF THE BODY

## CHICKENPOX



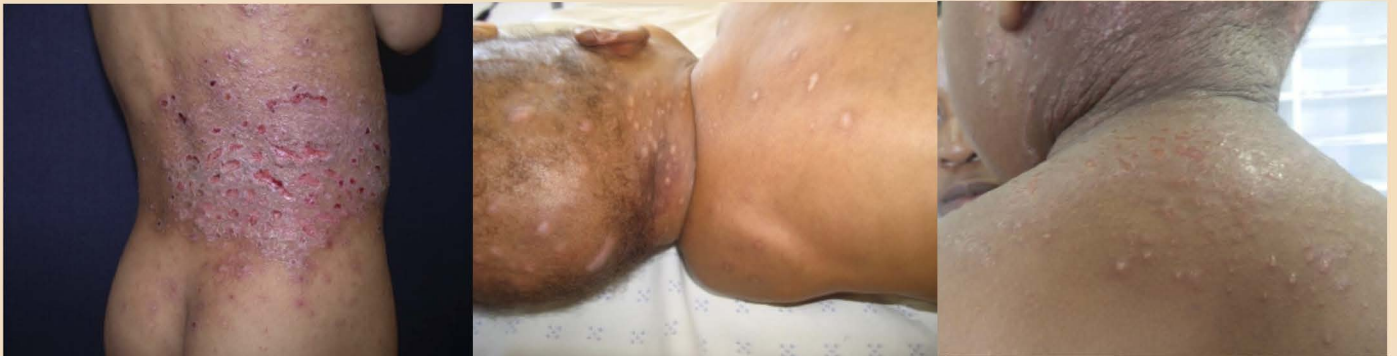**SOURCE:** Image from Brown Skin Matters <https://www.instagram.com/brownskinmatters/> (accessed 20/05/20)

**WHAT IT IS:** Chickenpox is caused by the Varicella Zoster Virus. It commonly occurs in childhood and is highly contagious but self-limiting for most of those affected. It presents with rash and fever.

**HOW IT IS IDENTIFIED:** Chickenpox is characterised by a widespread, itchy, papular rash. The small red papules may appear more subtle in dark skin but will soon develop into fluid filled blisters (vesicles). These may spread all over the body. Excoriation may increase the risk of secondary bacterial infection.

# REST OF THE BODY

## E C Z E M A H E R P E T I C U M



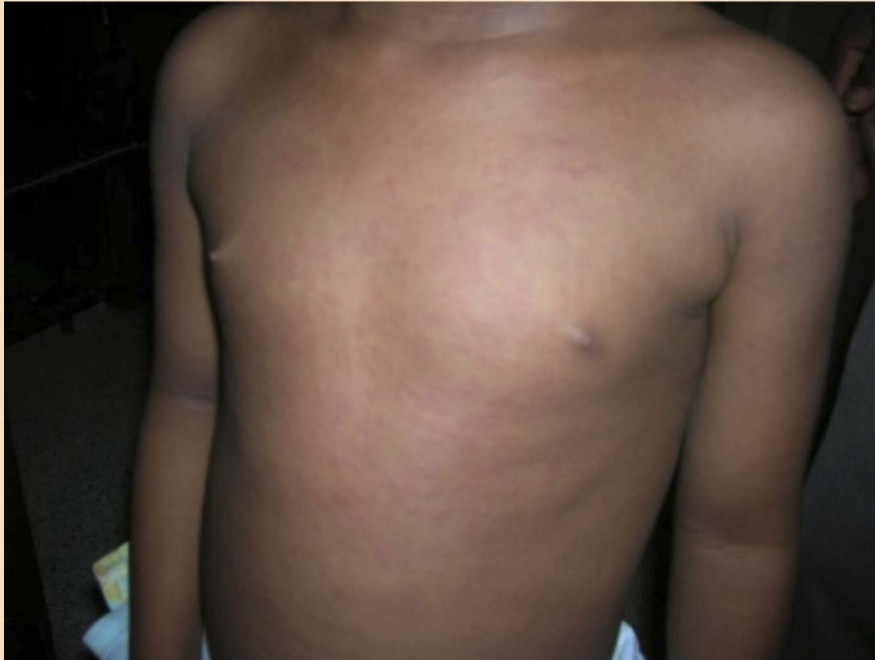**SOURCE:** Images (used under CC licence CC BY-SA 4.0) from Atlas of Paediatric HIV Infection. Oladokun R et al  
<https://openbooks.uct.ac.za/uct/catalog/view/hivatlas/23/655-2> (accessed 20/05/20)  
<https://creativecommons.org/licenses/by-sa/4.0/>

**WHAT IT IS:** Eczema Herpeticum is a serious viral infection associated with HSV1 or 2 (Herpes Simplex Virus). Those with severe eczema are at higher risk of developing it.

**HOW IT IS IDENTIFIED:** Eczema Herpeticum often presents with eruptions of multiple painful, itchy vesicles affecting the neck and face (right image) but other sites can be affected. They may crust and form erosions. The centre image shows scarring from residual lesions. These are depigmented (more pale than surround skin) and appear a light pinkish-brown colour. They may get slightly darker over time. It is not uncommon for deep excoriations caused by scratching due to the itchy nature of the rash (left image). This may lead to secondary bacterial infection. In darker skin tones atopic eczema may leave grey/silver patches and plaques.

# REST OF THE BODY

## MEASLES



**SOURCE:** Images (used under CC licence CC BY-SA 4.0) from Atlas of Paediatric HIV Infection.

Oladokun R et al

<https://openbooks.uct.ac.za/uct/catalog/view/hivatlas/23/662-1> (accessed 20/05/20)

<https://creativecommons.org/licenses/by-sa/4.0/>

**WHAT IT IS:** Measles is a viral condition which causes fever, coryza and a maculopapular rash

**HOW IT IS IDENTIFIED:** Small, white “Koplik spots” may be seen on the oral mucosa. A blotchy rash typically appears a few days after the initial symptoms. It starts in the head and neck and spreads to the trunk and rest of the body. Palms and soles are usually spared. The rash is non-itchy, it consists of macules (flat area of altered colour) and papules (raised areas <5mm diameter). These may become larger and merge to form patches. The rash will begin to fade after 3 or 4 days. Note the reddish undertone to the lesions, this may progress to a purple hue. Where the normal skin tone is dark the rash may be more subtle so it is important to expose the trunk fully and use adequate lighting.

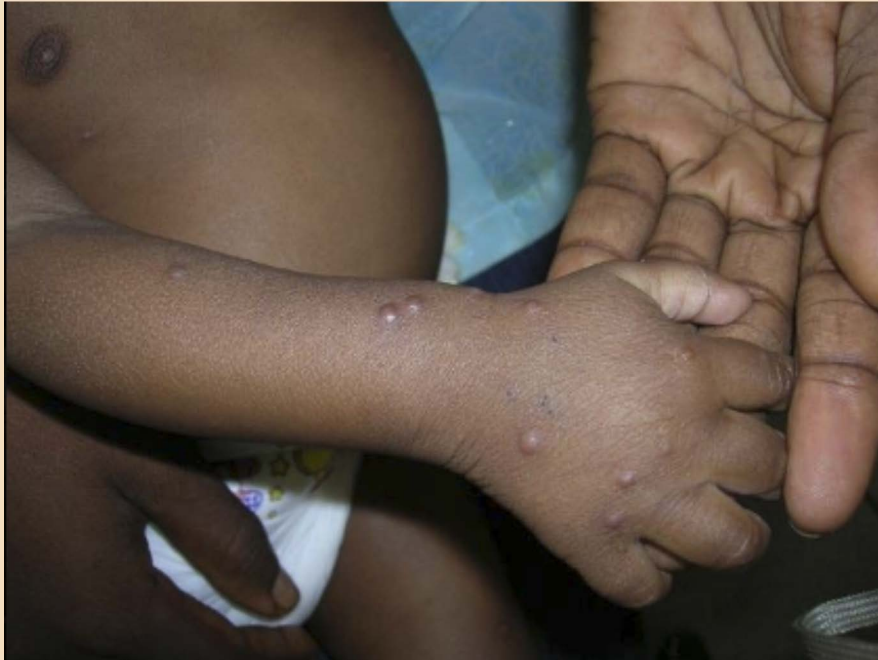**DESCRIPTION AMENDED FROM:** DermNet NZ <https://dermnetnz.org/topics/measles/>

(accessed 20/05/20)

---

# REST OF THE BODY

## MOLLUSCUM CONTAGIOSUM



**SOURCE:** Images (used under CC licence CC BY-SA 4.0) from Atlas of Paediatric HIV Infection. Oladokun R et al

<https://openbooks.uct.ac.za/uct/catalog/view/hivatlas/23/656-2> (accessed 20/05/20)

<https://creativecommons.org/licenses/by-sa/4.0/>

**WHAT IT IS:** Molluscum contagiosum is a common viral skin infection which presents with papules. It is most common in children, particularly in warm and overcrowded environments. It is more common for those with atopic eczema and more severe in those with immunosuppression (e.g. HIV).

**HOW IT IS IDENTIFIED:** Molluscum presents as clusters of small round papules. These are solid, raised lesions (<5mm diameter). Number of papules varies. They may be skin colour or take on a more pinkish tone. It is often associated with dermatitis, note the erythema on the back of the hand. Similar to other conditions, excoriation may increase the risk of secondary bacterial infection.

**DESCRIPTION ADAPTED FROM:** DermNet NZ

<https://dermnetnz.org/topics/molluscum-contagiosum/> (accessed 20/05/20)

# REFERENCES

- Gishen F.,Lokugamage A. Diversifying the Medical Curriculum,BMJ 2019; 364:1300
- Crawley J et al. Malaria in Children. The Lancet. 2010; 375.
- Breman J, Holloway C. Malaria surveillance counts. The American Journal of Tropical Medicine and Hygiene. 2007.
- Singhai A et al. Methemoglobinaemia. Journal of Dr. NTR University of Health Sciences. 2013.
- McMullen S, Patrick W. The American Journal of Medicine. Cyanosis. 2013.
- Oladokun R et al. Atlas of Paediatric HIV Infection.  
<https://openbooks.uct.ac.za/uct/catalog/view/hivatlas/23/655-2> (accessed 20/05/20)
- Matthews C et al. Sick cell disease in childhood. BMJ. 2014; 348
- Newcastle University. JIA Subtypes. <http://www.pmmonline.org/page.aspx?id=1643> (accessed 20/0520)
- Tully A et al. Evaluation of Nail Abnormalities. American Family Physician. 2012; 85(8)
- Oakley A (DermNet NZ). Melanoma of Nail Unit  
<https://dermnetnz.org/topics/melanoma-of-nail-unit/> (accessed 22/05/20)
- Desai V et al. Familial primary osteoarthropathy: A case report with unusual dental findings. Journal of Indian Academy of Oral Medicine and Radiology. 2015 (27)4: p620-624
- BMJ Best Practice: Assessment of Clubbing <https://bestpractice.bmj.com/topics/en-gb/623> (accessed 22/05/20)
- Ely J, Rosenfield S. Diagnosis and Management of Tinea Infections. American Family Physician. 2014; 90(10): p702-711
- British Association of Dermatologists. Tinea Capitis Patient Information Leaflet. 2014  
<https://www.bad.org.uk/for-the-public/patient-information-leaflets/tinea-capitis> (accessed 22/05/20)
- User: Sab3el3eish. Jaundice image. <https://commons.wikimedia.org/wiki/File:Jaundice.jpg> (accessed 20/05/20)
- Beta Charitable Trust. Goitre Operations.  
[www.betacharitabletrust.org/projects/goitre-operations](http://www.betacharitabletrust.org/projects/goitre-operations) (accessed 18/05/20)
- Starr O. Goitre. 2020  
<https://patient.info/hormones/overactive-thyroid-gland-hyperthyroidism/goitre-thyroid-swelling> (accessed 18/05/20)
- Oakley A (DermNet NZ). Meningococcal Disease  
<https://dermnetnz.org/topics/meningococcal-disease/> (accessed 20/03/20)
- Meningitis Research Foundation. Symptoms Checker for Babies.  
<https://www.meningitis.org/meningitis/check-symptoms/babies> (accessed 20/03/20)

# REFERENCES

Mayo Clinic. Ichthyosis Vulgaris. <https://www.mayoclinic.org/diseases-conditions/ichthyosis-vulgaris/symptoms-causes/syc-20373754> (accessed 18/05/20)

Tirgan M. Massive Keloids image [https://commons.wikimedia.org/wiki/File:Massive\\_Keloids.jpg](https://commons.wikimedia.org/wiki/File:Massive_Keloids.jpg) (accessed 18/05/20)

Tirgan M. Keloid Face image. [https://commons.wikimedia.org/wiki/File:Keloid-Face\\_Semi\\_Flat,\\_Facial\\_Keloid.JPG](https://commons.wikimedia.org/wiki/File:Keloid-Face_Semi_Flat,_Facial_Keloid.JPG) (accessed 18/05/20)

Garikai S. Bruising image. 2020

Brown Skin Matters IG <https://www.instagram.com/brownskinmatters/> (accessed 20/05/20)

Martin E (ed). Concise Medical Dictionary. OUP: Oxford; 9<sup>th</sup> edition; 2015

Knott L. Leg Ulcers. <https://patient.info/doctor/leg-ulcers-pro> (accessed 20/05/20)

Oakley A (DermNet NZ). Blistering skin condition. <https://dermnetnz.org/topics/blistering-skin-conditions/> (accessed 20/05/20)

Oakley A (DermNet NZ). Measles. <https://dermnetnz.org/topics/measles/> (accessed 20/05/20)

Oakley A, Vanousova D (DermNet NZ). Molluscum contagiosum. <https://dermnetnz.org/topics/molluscum-contagiosum/> (accessed 20/05/20)

---

# **WANT TO CONTRIBUTE?**

**IF YOU THINK YOU THINK THERE IS SOMETHING MISSING FROM THIS HANDBOOK AND WOULD LIKE TO SEE MORE CONDITIONS INCLUDED THEN WE ARE ALWAYS LOOKING FOR CONTRIBUTORS. IN PARTICULAR WE WOULD WELCOME CLINICAL SIGNS FOR THE CHEST, ABDOMEN, AND LOWER LIMBS (VASCULAR).**

**IT IS VERY EASY TO CONTRIBUTE:**

- 1. VISIT [WWW.BLACKANDBROWNSKIN.CO.UK](http://WWW.BLACKANDBROWNSKIN.CO.UK)**
- 2. CLICK ON 'SUBMISSIONS' UNDER 'WAYS TO HELP'**
- 3. FOLLOW THE INSTRUCTIONS PROVIDED**

**IDEAS FOR CONTRIBUTIONS:**

- GYNAECOMASTIA**
- SPIDER NAEVI**
- ASCITES**
- CAPUT MEDUSAE**
- STRIAE**
- CULLEN/GREY-TURNER SIGNS**
- VENOUS ECZEMA & ASSOCIATED SIGNS**
- DIABETIC FOOT ULCER**
- LYME DISEASE**



# MIND THE GAP

ISBN 978-1-5272-6908-8



9 781527 269088 >

[www.blackandbrownskin.co.uk](http://www.blackandbrownskin.co.uk)